

# South Shore Equine Clinic & Diagnostic Center

151 Palmer Road

Plympton, MA 02367

781-585-2611

[www.ssequineclinic.com](http://www.ssequineclinic.com)

## EYE EMERGENCIES

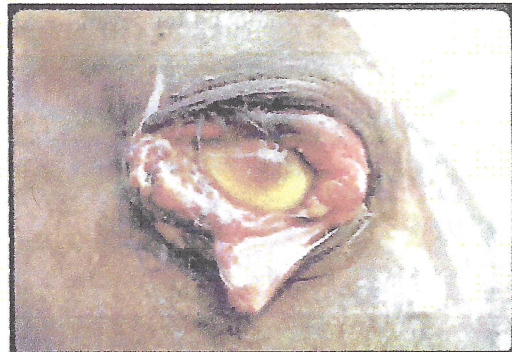Injuries to the eye and surrounding areas of the head and face are relatively common in horses and ponies due to their inquisitive nature and as a result of 'arguments' with each other and with structures such as stable doors, fence posts, trees etc. Foreign material such as grass seeds, thorns etc. may cause abrasions to the cornea (surface) or may even puncture the eye. A kick or other blow can cause serious damage to the eye as well as the eyelids and bones underneath.

### Conjunctivitis

This is not an emergency condition but can appear similar to, and often accompanies more serious problems. Conjunctivitis is inflammation of the mucous membrane (pink lining) which surrounds the eyeball and lines the inner surface of the eyelids. This inflammation may be due to dust or fly irritation or can be due to infection. Most simple cases improve quickly with eye drops or ointment which can be prescribed by your veterinary surgeon.

### Injuries to the eyelids and deeper tissues

This can range from bruising to full thickness wounds of the eyelids or surrounding tissues. Severe bruising may be associated with fracture of the bones around the eye. Your veterinarian should be called to examine any eye injury involving swelling around the eye or cuts to the eyelids. The eye itself may also be damaged. Sedation may be required in order to perform a thorough assessment of the injury if the region is very painful or the horse difficult to examine. Eyelid injuries usually require surgical suturing. Severe damage may necessitate reconstructive surgery under general anaesthesia.

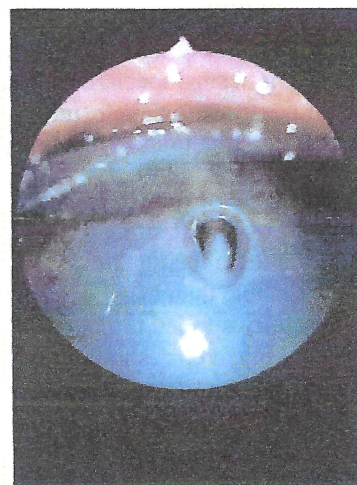


*Traumatic injury to eye and eyelid.*

### Injuries to the eyeball

Blunt trauma, such as a blow to the eye, can cause inflammation and bleeding into the eye. In some cases the surface (cornea) of the eye is damaged, usually causing an ulcer. If the ulcer is only superficial, the cornea heals quickly with minimal or no adverse effect to the eye or its sight. Severe damage however, can result in perforation or laceration of the cornea, resulting in rupture of the eyeball. Between these two extremes lies a whole range of injuries which can involve any or all of the internal structures of the eye.

Any injury to the eye is painful. There is usually a marked increase in tear production causing a watery eye. The



*Corneal ulcer.*



# South Shore Equine Clinic & Diagnostic Center

151 Palmer Road

Plympton, MA 02367

781-585-2611

[www.ssequineclinic.com](http://www.ssequineclinic.com)

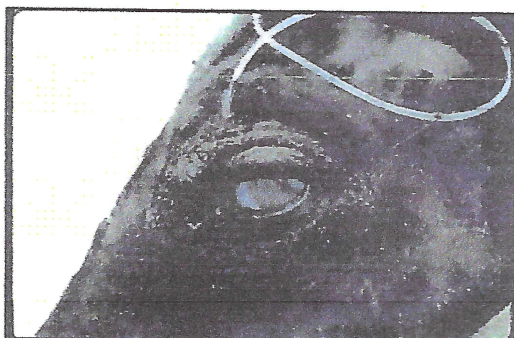conjunctiva becomes inflamed and appears redder than normal and the eye may be held tightly closed. You should call your veterinarian if your horse is showing these symptoms. During the early stages of inflammation and healing, the eye may appear cloudy or may contain blood and strands of yellowish material (fibrin and inflammatory debris). The pupil will tightly constrict in a painful eye.

Your veterinarian can apply some green (fluorescent) dye to demonstrate damage to the cornea. The eye can also be examined for internal damage with the use of an ophthalmoscope. To look into a horse's eye thoroughly, your veterinarian will need the horse to be co-operative and be in a darkened stable.

## Management of eye injuries

Always seek early veterinary advice following an eye injury to your horse or pony. In most cases treatment will involve the use of eye ointment or drops in combination with oral or injectable anti-inflammatory and/or antibiotic medication. Do not use eye drops or ointments prescribed for another horse as they might contain the wrong medication or may spread infection.

Eye ointments and drops usually need to be applied several times a day. In some cases this treatment must be continued for several weeks. It is important that medication goes into the



*Indwelling tube inserted under eyelid to facilitate remote treatment.*

eye rather than onto the eyelids and lashes. Ask for help if necessary. The use of a twitch may help to keep the horse's head still but beware of horses or ponies who hate the twitch as they can strike out with their front legs. If you continue to have trouble administering the treatment, speak to your veterinary surgeon about alternative methods. In some severe injuries or in particularly difficult horses, it is possible to surgically place an indwelling polyethylene tube through the eyelid, allowing repeated treatments to be made remotely from the eye.

Some penetrating injuries require suturing of the eye itself, which is performed under general anesthesia, using specialized surgical equipment. Some corneal injuries require tissue grafts or temporary surgical closure of the eyelids, to protect the wound until it heals. Rupture of or extreme trauma to the eyeball usually necessitates removal of the eye.

If your horse or pony has an eye injury or infection, the eye will be less painful if the horse is kept out of bright sunlight or other light source. A horse with a painful closed eye is more susceptible to being kicked or injured by another horse and may be more nervous and unpredictable than usual when approached on the injured side. A fly repellent preparation can be carefully applied to the horse's face, not in contact with the eyes, to minimise irritation by insects. Fly 'veils' should be avoided as these may rub or hit the eye. The newly available eye and face nets may be helpful.